

# Early Outcomes of an Artificial Endothelial Replacement Membrane Implantation After Failed Repeat Endothelial Keratoplasty

Luigi Fontana, MD, PhD,\*† Natalie di Geronimo, MD,\*† Michela Cennamo, MD,‡ Rita Mencucci, MD,‡  
Piera Versura, BSD,\*† and Antonio Moramarco, MD\*†

**Purpose:** The purpose of this study was to report the outcomes of a novel artificial endothelial replacement membrane implant for treating corneal edema after failed repeat endothelial keratoplasty (EK).

**Design:** This was a retrospective interventional case series.

**Methods:** Patients with chronic corneal edema underwent removal of the EK graft and implantation of an artificial endothelial replacement membrane (EndoArt, EyeYon Medical, Israel) several months after 2 or more Descemet stripping endothelial keratoplasty procedures. The implant was secured to the posterior corneal surface using an air–gas bubble. Outcome measures included corrected distance visual acuity (logMAR), central corneal thickness, device-related complications, and ocular discomfort.

**Results:** Five eyes of 5 patients underwent EndoArt implantation. Six months after surgery, the synthetic endothelial replacement membrane was well-centered and adherent to the posterior corneal surface, with improvement in central corneal transparency in all patients. Corrected distance visual acuity increased from mean  $1.26 \pm 0.25$  (logMAR) preoperatively to  $0.74 \pm 0.44$  (logMAR) postoperatively ( $P = 0.06$ ). Central corneal thickness significantly decreased from a mean of  $805 \pm 135 \mu\text{m}$  (excluding the EK graft) preoperatively to  $588 \pm 60 \mu\text{m}$  (excluding the EndoArt) postoperatively ( $P = 0.015$ ). No severe device-related complications developed after surgery, although most patients required more than 1 air–gas bubble injection to achieve complete implant adhesion. All

patients experienced preoperative reduction in subjective ocular pain.

**Conclusions:** Synthetic endothelial replacement membrane implantation improves central corneal transparency and visual acuity in patients with failed EK and guarded prognosis for repeat keratoplasty. No significant implant-related adverse events occurred after surgery.

**Key Words:** artificial endothelial keratoplasty, bullous keratopathy, corneal graft failure, DSEK, late endothelial graft failure, endothelial transplantation, corneal edema

(*Cornea* 2023;00:1–7)

Endothelial keratoplasty (EK), currently using Descemet stripping endothelial keratoplasty (DSEK) or Descemet membrane endothelial keratoplasty (DMEK), is the treatment of choice for patients with all types of corneal endothelial dysfunction.<sup>1</sup>

Because of the recognized advantages of minor invasiveness, faster visual recovery, and a higher safety profile, EK has largely superseded penetrating keratoplasty (PK), becoming the new gold standard of treatment for patients with corneal edema due to endothelial failure.<sup>2</sup> In 2022, in the United States, only 10.1% of patients with various forms of endothelial dysfunction were treated with PK, whereas 89.9% received one form of EK.<sup>2</sup>

The probability of success of primary EK is high, ranging from 83% to 96% at 5 years after DMEK<sup>3,4</sup> and from 79.4% to 96% after DSEK.<sup>5,6</sup> However, concerns regarding long-term graft survival are relevant, particularly in some patients. Prior graft failure, bullous keratopathy, glaucoma, and previous complicated anterior segment surgery are negative prognostic factors for graft survival, with an overall probability of requiring repeat keratoplasty of 14.3% at 5 years and up to 26% in eyes with a failed graft.<sup>7</sup> Repeat keratoplasty has become the second most frequent indication for corneal transplantation in the United States, accounting for 15.2% of graft surgeries performed in 2022.<sup>2</sup> Of these, 52.6% underwent repeat EK. Similar to PK, the expected survival time of repeat EK decreases with the number of previous graft procedures.<sup>7–9</sup> For this reason, the burden of repeat EK procedures is expected to increase, given the expanding number of EK surgeries performed worldwide and the

Received for publication July 21, 2023; revision received September 23, 2023; accepted September 28, 2023.

From the \*Ophthalmology Unit, Dipartimento di Scienze Mediche e Chirurgiche, Alma Mater Studiorum University of Bologna, Bologna, Italy; †IRCCS Azienda Ospedaliero-Universitaria di Bologna, Bologna, Italy; and ‡Ophthalmology Unit, Azienda Ospedaliero-Universitaria Careggi, UNIFARBA Department, University of Florence, Florence, Italy.

The authors have no funding or conflicts of interest to disclose.

Supplemental digital content is available for this article. Direct URL citations appear in the printed text and are provided in the HTML and PDF versions of this article on the journal's Web site ([www.corneajrnl.com](http://www.corneajrnl.com)).

Correspondence: Luigi Fontana, MD, PhD, Ophthalmology Unit, Policlinico S. Orsola di Bologna, Via Pelagio Palagi 9, Bologna 40138, Italy (e-mail: [luifonta@gmail.com](mailto:luifonta@gmail.com)).

Copyright © 2023 The Author(s). Published by Wolters Kluwer Health, Inc. This is an open access article distributed under the terms of the Creative Commons Attribution-Non Commercial-No Derivatives License 4.0 (CCBY-NC-ND), where it is permissible to download and share the work provided it is properly cited. The work cannot be changed in any way or used commercially without permission from the journal.

application of EK to treating patients with complicated anterior segment conditions.<sup>10</sup>

A potential solution to this issue may come from the introduction of a novel device named EndoArt (EndoArt, Eye Yon Medical, Israel), a CE-approved device for the treatment of corneal edema comprised an acrylic hydrophilic, flexible material measuring 50  $\mu\text{m}$  thickness and 6.5 mm in diameter, shaped according to the posterior corneal curvature, which acts as an artificial fluid barrier to replace the function of the diseased corneal endothelium. Once the device adheres to the inner corneal surface, aqueous penetration into the central corneal stroma is prevented, resulting in a reduction in stromal edema and improvement in corneal transparency.

In this study, we report the early clinical outcomes of a series of consecutive patients with chronic corneal edema after a failed DSEK who underwent EndoArt implantation.

## METHODS

This retrospective case series was approved by the hospital's Institutional Review Board (Registration No. 901/2022/Oss/AOUBo) and adhered to the tenets of the Declaration of Helsinki. Ad hoc informed consent for EndoArt implantation and the collection of personal data were obtained from all participants. Patients with chronic corneal edema with 2 or more previously failed EK grafts awaiting repeat posterior lamellar keratoplasty were selected and interviewed to assess their willingness to undergo artificial endothelial replacement membrane implantation.

We excluded patients with corneal stromal opacities and extensive peripheral anterior synechiae, which may have limited the visual outcome and complicated device implantation. Furthermore, cases of the absence of complete irido-capsular diaphragm (partial or complete aniridia, anterior chamber (AC) secondary intraocular lens implant, etc.) and glaucoma shunt implantation were excluded because of the risk of early loss of the AC air–gas bubble hindering device attachment.

After surgery, patients were followed up at our clinic on days 1, 7, 15, and 30 and then monthly according to the follow-up course. Corrected distance visual acuity (CDVA) (logMAR), slitlamp examination, intraocular pressure (IOP) (Goldman tonometer, Haag-Streit, Koeniz, Switzerland), and anterior segment optical coherence tomography (AS-OCT) (Casia II, Tomey Corp, Nagoya, Japan) were recorded at each preoperative and postoperative visit. Fundus examination and macular OCT (SPECTRALIS OCT, Heidelberg Engineering, Heidelberg, Germany) were performed postoperatively. Central corneal thickness (CCT) was calculated using AS-OCT by measuring the distance between the external and internal corneal surfaces at the apex using calipers, excluding the EK graft and the EndoArt implant. The number of intraoperative and postoperative implant-related complications was recorded.

We used the verbal numerical rate score (NRS) to assess the patient's preoperative and postoperative ocular discomfort.<sup>11</sup>

The outcome measures of this study were CDVA and CCT measured at baseline and 6 months after surgery, implant-related complications, and NRS scores.

## Statistical Analysis

Clinical variables, CDVA, and CCT were expressed using the mean  $\pm$  SD. Variables were compared using a paired sample *t* test. Statistical significance was set at  $P < 0.05$ . Statistical analyses were performed using SPSS for Windows version 25 (IBM Corp, Armonk, NY).

## In vivo confocal microscopy (IVCM)

Morphological analysis of the central cornea and the implant interface was performed using IVCM (Heidelberg Retina Tomograph III Rostock cornea-module, Heidelberg Engineering GmbH, Germany). The examination was conducted as previously described.<sup>12</sup> Multiple scans with a field of view of 400  $\mu\text{m} \times 400 \mu\text{m}$  were acquired by an experienced user (M.C.). Scans taken from the central and paracentral zones (superior, inferior, nasal, and temporal corneal quadrants) were evaluated as averages of at least 2 images using IVCM Heidelberg proprietary software. All layers of the corneal zone were investigated from the epithelium to the implanted device.

## Surgical technique (see surgery video)

All patients underwent surgery by a single surgeon (L.F.) at the same institution (Ospedale S. Orsola, Bologna, Italy). Surgeon was well experienced in EK surgery but novel to EndoArt implantation. The procedures were performed under local anesthesia.

In brief, using a temporal approach, the corneal epithelium was removed to improve visualization, and an AC maintainer was used to avoid hypotony. The EK graft was detached from the posterior stroma using a reversed Sinskey hook (Moria SA, Nanterre, France) and extruded from the AC through a 2.0-mm temporal corneal tunnel. If not present, an inferior iridotomy was performed at 6 o'clock using an anterior vitrectome (Alcon Laboratories Forth Worth, TX). The EndoArt implant was then placed over the corneal surface to check for integrity and correct orientation, according to the "F" mark visible at 1 edge. A blunt tip spatula (Janach Srl, Como, Italy) was used to push the device through corneal tunnel-promoting device coiling during the passage. Once inserted into the AC, the implant spontaneously unfolded and was centered on the visual axis. Subsequently, a bubble of air mixed with 10% perfluoropropane (C3F8) was injected into the AC to elevate the device and favor its adherence to the posterior corneal surface. A single 10.0 nylon transfixing suture was used to secure the device to the cornea for 3 months and then removed. Microscope-integrated OCT (Leica Biosystems, Nussloch, Germany) was used to confirm complete adhesion of the device at the end of surgery. A soft bandage contact lens was placed over the cornea to promote epithelial healing.

Postoperative medication included tobramycin 0.3% and dexamethasone phosphate 0.1% eye drops 4 times daily for the first month, twice daily for the second and third months, and then suspended.

### Case 1

A 76-year-old woman with chronic corneal edema in 1 eye after 2 DSEK procedures for bullous keratopathy was referred for a repeat EK surgery. On examination, her CDVA was 1.5 logMAR (20/630 Snellen) in her left eye and IOP was 12 mm Hg after treatment with 1 medication. Slitlamp inspection revealed diffuse pseudophakic bullous keratopathy and posterior EK graft thickening with a CCT of 787  $\mu$ m. The preoperative NRS score was rated 7.5. Considering the probability of short-term graft failure with repeated EK, we proposed EndoArt implantation in the left eye.

On the first postoperative day, the cornea was clear, with the implant well positioned, and the CCT was 578  $\mu$ m. At 2 weeks with a 40% AC air–gas fill, partial detachment and temporal decentration of the device occurred, requiring implant repositioning and a new AC air gas (C3F8 10%) bubble injection. Two months later, a second rebubbling was performed because of partial detachment of the implant. At 6 months after surgery, the CDVA was 0.4 logMAR (20/50 Snellen), IOP was 15 mm Hg on the same preoperative hypotensive treatment, the artificial endothelial replacement membrane was well positioned, CCT was 636  $\mu$ m, and NRS score was 4.

### Case 2

A 75-year-old man with a history of glaucoma and pseudophakic corneal decompensation with 2 previous DSEK graft surgeries in his right eye presented at our examination. At the first visit, the CDVA was 1.0 logMAR (20/200 Snellen) in the right eye and IOP was 13 mm Hg on 2 glaucoma medications. Slitlamp examination of the right eye revealed diffuse stromal edema with a CCT of 775  $\mu$ m. The preoperative NRS score was 6.5.

At day 1 postoperatively, the cornea was clear, the implant was well-centered, and the CCT decreased to 540  $\mu$ m. One month postoperatively, once the air–gas bubble was reabsorbed, the cornea was clear with a CCT of 592  $\mu$ m, but the CDVA was only 0.8 logMAR (20/125 Snellen). Macular OCT showed the signs of cystoid macular edema (CME), which accounted for the marginal improvement in visual acuity. Two months postoperatively, the patient reported decreased vision and slitlamp examination revealed partial detachment of the artificial endothelial replacement membrane with an increased CCT of 860  $\mu$ m. The patient underwent a new air–gas bubble injection. At 6 months, the IOP was 17 mm Hg on the same preoperative treatment, the central cornea was clear with a CCT of 629  $\mu$ m, and the implant was adherent; however, the CDVA remained 0.8 logMAR due to chronic CME. A slight reduction in ocular discomfort was recorded, with an NRS score of 5.

### Case 3

A 75-year-old woman came to our attention, referring worsening of vision in her left eye. She had a long history of glaucoma in the same eye with a trabeculectomy followed by phacoemulsification. Eventually, owing to poor IOP control, a second trabeculectomy was performed. A few years later, she developed corneal endothelial failure with bullous keratopathy for which she underwent DSEK. After graft decompensation, repeat DSEK was performed 2 years later and a third after 4 years. At the examination, left eye CDVA was 1.5 logMAR (20/630 Snellen), slitlamp analysis showed corneal edema with a CCT of 1036  $\mu$ m, and the IOP was 16 mm Hg without therapy. The preoperative NRS score was 5.5.

On day 1 postoperatively, the corneal edema resolved and the CCT was 531  $\mu$ m. At 1 month, the implant was partially detached with an edematous cornea, and a second AC air–gas bubble was required. One month later, the cornea was clear, the CCT was 529  $\mu$ m, and the CDVA was 1.3 logMAR (20/400 Snellen). Fundus examination revealed advanced glaucomatous damage to the optic nerve. At 6 months, the cornea was clear and the artificial endothelial replacement membrane was adherent with a CCT of 613  $\mu$ m. The CDVA was 1.0 logMAR (20/200 Snellen), and the IOP was 16 mm Hg. A slight pain reduction was recorded, with an NRS score of 3.5.

### Case 4

A 72-year-old woman was referred to our hospital with chronic endothelial graft failure in the left eye. Four years earlier, she underwent DMEK for corneal decompensation after trabeculectomy and phacoemulsification, followed by dexamethasone 0.7 mg intravitreal implantation to treat CME. A second DMEK was performed 3 years later because of graft failure. At examination, the CDVA was 1.0 logMAR (20/200 Snellen) in the left eye. Slitlamp examination showed diffuse corneal edema with a CCT of 691  $\mu$ m. The IOP was 19 mm Hg after therapy with 3 medications. The mean preoperative NRS score was 5. We performed artificial endothelial replacement membrane implantation with the patient's consent.

On the first postoperative day, the implant was well adherent and the corneal edema resolved. Nonetheless, 3 weeks after surgery, edema reappeared due to a partially detached implant and a new air–gas bubble was injected. One month later, the cornea was clear, CDVA was 1.3 logMAR (20/400 Snellen), and CCT was 551  $\mu$ m. Macular OCT revealed the signs of CME. Four weeks later, a second rebubbling was required because of another implant detachment. During follow-up, the patient developed elevated IOP at 30 mm Hg, despite maximum tolerated topical treatment, but refused to undergo a further glaucoma surgical procedure. At 6 months, best-corrected visual acuity was still 1.3 logMAR (20/400 Snellen), the central cornea was clear with an adherent implant, and the CCT was 489  $\mu$ m. Despite maximum treatment, IOP remained elevated (30 mm Hg). Only a slight pain reduction was recorded (NRS score, 2.5).

## Case 5

A 78-year-old man was referred to our clinic because of worsening visual acuity in the right eye. He had a history of corneal decompensation after bilateral phacoemulsification surgery, for which he underwent bilateral DSEK. Four years later, both grafts failed and a repeat DSEK was performed in each eye. When he came to our attention, the cornea in the right eye was cloudy and edematous, the CDVA was 1.3 logMAR (20/400 Snellen), the IOP was 14 mm Hg, and the CCT was 734  $\mu$ m. The mean preoperative NRS score was 9.5. On the first postoperative day, the implant was adherent, the cornea was clear, and CCT was 519  $\mu$ m. Six months after surgery, the CDVA was 0.2 logMAR (20/32 Snellen), the artificial endothelial replacement membrane was attached, the central cornea was clear with a CCT of 573  $\mu$ m, and the IOP was 12 mm Hg. Significant pain relief was recorded (NRS score, 4.5).

## RESULTS

We reviewed the clinical records of 5 consecutive patients with chronic corneal edema who underwent artificial endothelial transplantation using the EndoArt device between August and November 2022 at the IRCCS-Azienda Ospedaliera di Bologna. Four patients had 2 and 1 had 3 previous EK procedures before EndoArt implantation. The mean interval between the last EK procedure and artificial device implantation was  $3 \pm 1$  year.

Six months after surgery, the EndoArt device adhered entirely to the posterior corneal surface and the central cornea was clear in all patients (Fig. 1).

The mean preoperative and last postoperative CDVA was  $1.26 \pm 0.25$  logMAR and  $0.74 \pm 0.44$  logMAR, respectively ( $P = 0.062$ ). After surgery, the visual acuity improved by 11 lines in 2 cases, 2 to 5 lines in 2 patients, and decreased by 3 lines in 1 patient. The mean CCT significantly changed from  $805 \pm 135$   $\mu$ m preoperatively to  $588 \pm 60$   $\mu$ m 6 months postoperatively ( $P = 0.015$ ), with a remarkable CCT reduction

occurring in all patients (Fig. 2). Corneal stromal thickening with peripheral epithelial bullae was visible on the slitlamp outside the area internally covered by the implant (Fig. 3).

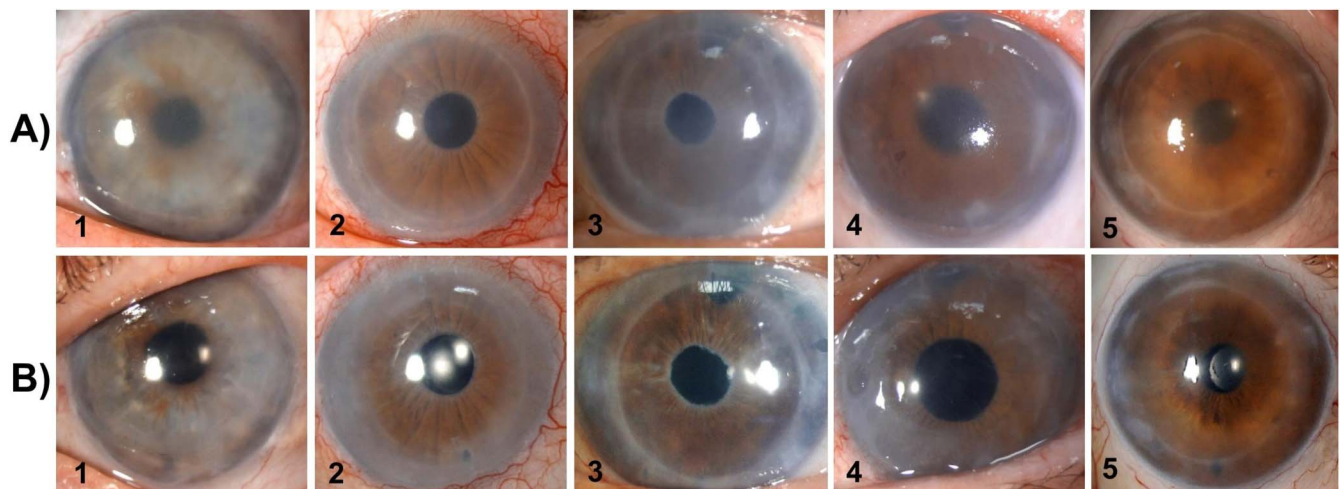
None of the patients developed significant complications related to the implant, but 4 of 5 patients required more than 1 air–gas bubble injection to achieve and maintain complete adhesion of the device to the posterior corneal surface. In these patients, implant detachment occurred 2 to 8 weeks after surgery. One patient (patient 4) who had previous filtration surgery and compensated IOP on treatment preoperatively developed increased IOP after surgery, despite maximum tolerated medical treatment. By contrast, in 3 patients with medically managed glaucoma and 1 patient with previous glaucoma surgery, IOP remained compensated in the same hypotensive preoperative regime.

Postoperatively, all patients experienced relief of subjective pain, with an NRS reduction ranging from 1.5 to 5 points.

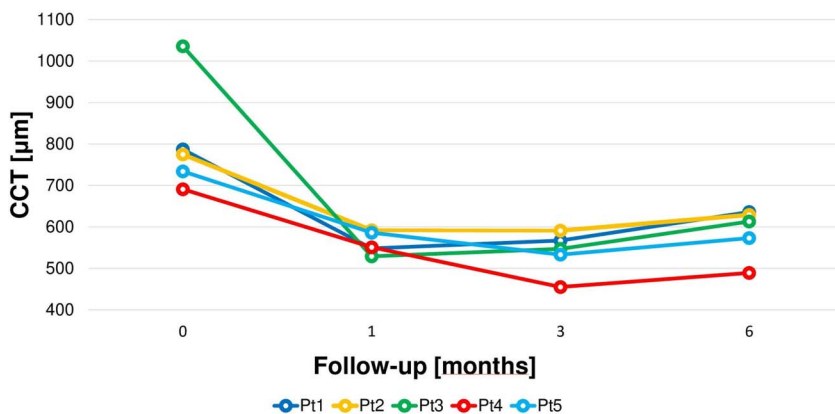
The IVCN identified a morphologically normal epithelium with a mild hyperreflective background as a sign of previous chronic corneal edema (Fig. 4). The subbasal plexus was clearly visible, showing broken and damaged nerve fibers. In the stromal layer, we observed, among normally shaped and spaced keratocytes, some rare hyperreflective keratocytes and partially disarranged stromal lamellae, suggesting residual signs of stromal edema. Scanty dendritic cells were also visible in the stroma, whereas needle-like hyperreflective bodies were detected at the stromal level, probably because of a subtle fibrosis process related to chronic changes induced by long-standing BK. The implant–recipient interface showed inhomogeneous hyperreflective haze with the absence of cells. The EndoArt implant appeared as an amorphous, acellular layer.

## DISCUSSION

Despite the favorable probability of DSEK graft survival (77%) at 15years,<sup>13</sup> the proportion of EK regrafts



**FIGURE 1.** Slitlamp photographs of patients 1 to 5 preoperatively (A) and postoperatively (B), 6 months after artificial endothelial replacement membrane implantation. Images show considerable improvement in central corneal transparency after surgery. (The full color version of this figure is available at [www.corneajrnl.com](http://www.corneajrnl.com).)



**FIGURE 2.** CCT measurements before (time 0) and at 1, 3, and 6 months after artificial endothelial replacement membrane implantation. A significant reduction in CCT was observed in all patients. (The full color version of this figure is available at [www.corneajrnl.com](http://www.corneajrnl.com).)

is rising. Patients with pseudophakic or aphakic bullous keratopathy (PBK, ABK) or failed PK have a worse prognosis for graft survival than those treated for Fuchs endothelial corneal dystrophy. In a recent study, Patel et al<sup>14</sup> reported higher graft survival in patients with Fuchs endothelial corneal dystrophy (77%) and significantly lower survival for recipients diagnosed with PBK (40%) 12 years after DSEK. In these patients, preexisting diagnosis of glaucoma and previous filtration surgery were independent adjunctive risk factors for short-term graft failure.

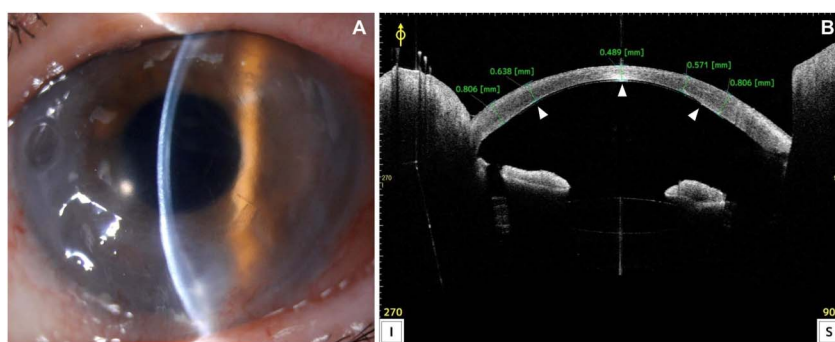
Late endothelial failure (LEF) can be defined as the gradual decompensation of a previously grafted cornea with stromal thickening and loss of clarity ascribable to progressive endothelial instability.<sup>15</sup> Given the increasing number of EK procedures worldwide, the management of LEF after keratoplasty is becoming increasingly relevant. A recent national transplant registry study conducted in the United Kingdom<sup>9</sup> reported a rapid surge in regrafts during the past decade, mainly referable to the learning curve acquisition of EK procedures.

In this study, we report our early experience of using an artificial endothelial replacement membrane to treat LEF in patients who underwent at least 2 EK procedures for various diagnoses. The mean interval between the last EK procedure and the artificial device implantation was 3 years. Three patients were on hypotensive topical treatment for glaucoma at the time of surgery, and 2 of them had previous incisional glaucoma surgery. In light of the low probability of success of

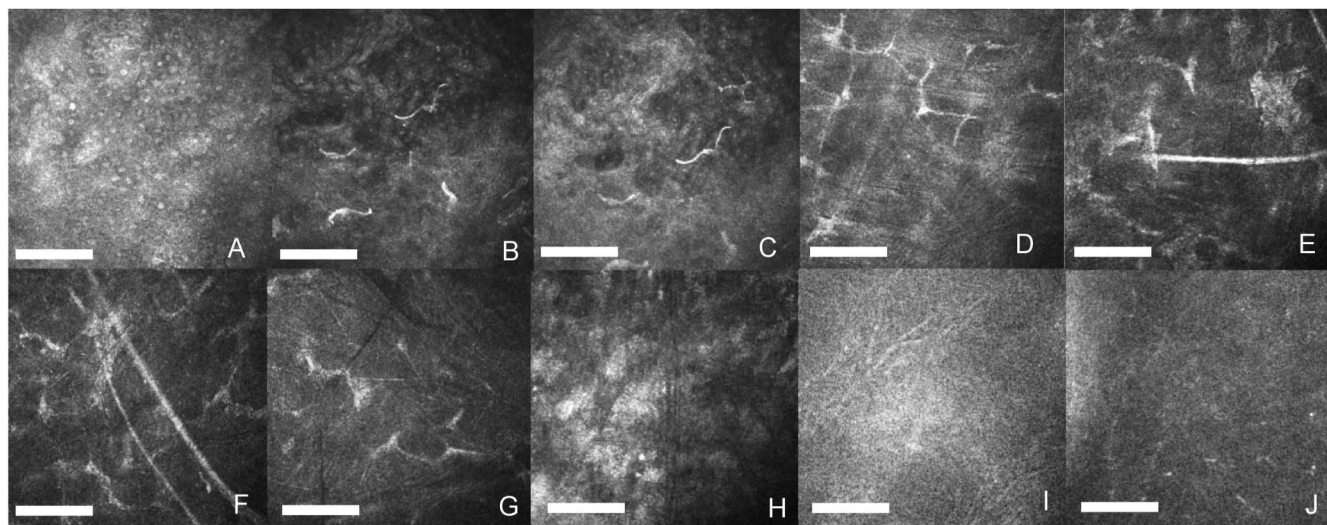
a repeat EK procedure in these patients, we proposed the implantation of an artificial device that may prompt corneal deturgescence with a potentially unlimited duration.

In a previous case series including 2 patients with bullous keratopathy after failed DMEK, Auffarth et al<sup>16</sup> described the rapid resolution of corneal edema after EndoArt implantation, with only marginal improvement in visual acuity due to ocular comorbidities. Both patients maintained a clear cornea for more than 1 year after device implantation without development of complications. Similarly, in our patients, rapid deturgescence of corneal edema was readily achieved and maintained throughout follow-up. Improvement in visual acuity was accomplished in all but 1 patient. A remarkable increase in the logMAR chart of 11 lines was recorded in 2 patients with mild or absent ocular comorbidities, while a more limited improvement of 2 to 5 lines occurred in 2 patients with CME (patient 2) and advanced optic nerve cupping (patient 3). Worsening of preoperative vision developed in 1 glaucomatous patient (patient 4) due to IOP decompensation after surgery. Interestingly, in this patient, notwithstanding the elevated ocular pressure (30 mm Hg), the central cornea remained clear, suggesting that the deturgescence efficacy of the device may remain effective despite the pressure. The risk of IOP decompensation in medically and surgically managed glaucoma after EK surgery is well documented<sup>13,17</sup> and represents a significant cause of rapid graft failure. This may be of less concern after

**FIGURE 3.** A, Slitlamp photograph 6 months after artificial endothelial replacement membrane implantation (patient 4). The image shows a clear central cornea (5–6-mm diameter) corresponding to the area of the implant. The letter F used for device orientation is visible. The peripheral cornea is edematous and opaque. B, AS-OCT of the same patient. The AS-OCT shows the artificial endothelial replacement membrane well adherent to the posterior corneal surface (arrowheads). The calipers indicate the corneal thickness excluding the implant. (The full color version of this figure is available at [www.corneajrnl.com](http://www.corneajrnl.com).)







**FIGURE 4.** IVCN analysis of patient 4, conducted 6 months after artificial endothelial replacement membrane implantation. A, Superficial epithelial layer (depth 32  $\mu\text{m}$ ) showing mild hyperreflective background. B, C, Subbasal plexus layer displaying broken and damaged nerve fibers (depth 60  $\mu\text{m}$ ). D, Hyperreflective keratocytes in the anterior stromal layer (depth 200  $\mu\text{m}$ ). E, F, Needle-shaped elements in the anterior stroma (depth 250  $\mu\text{m}$ ). G, Partial lamellar disarrangement in the posterior stroma (depth 400  $\mu\text{m}$ ). H, Interface between artificial endothelial replacement membrane and recipient posterior stroma surface showing mild hyperreflectivity and absence of cells (depth 500  $\mu\text{m}$ ). I, J, Artificial endothelial replacement membrane showing amorphous acellular homogeneous reflectivity (depth 550  $\mu\text{m}$ ). Bar 100  $\mu\text{m}$  (original magnification 300).

implantation of an artificial endothelial replacement membrane.

The EndoArt was inserted using a “push through” technique where the device was forcibly introduced into the AC through a 2.0-mm corneal libel incision using a blunt tip spatula. Owing to its flexibility, the device spontaneously coiled, passing through the corneal tunnel, and unfolded slowly once into the AC. In our experience, the device easily maintains its correct orientation using this implantation technique. However, if the implant is turned over during insertion, it may be safely manipulated using the F mark for orientation without the risk of damage.

The main difficulty we experienced using EndoArt is the promotion and achievement of stable adhesion to the posterior stromal surface. We injected air mixed with 10% CAFE into the AC and a temporary transfixing 10.0 nylon suture to secure the implant to the posterior corneal surface for a prolonged period. Despite this, graft detachment occurred, within 2 months from surgery, in 4 of 5 patients who required 1 or 2 air–gas bubbles to obtain implant attachment. Part of this difficulty may be explained by our inexperience in using this device. In some cases, we noticed on AS-OCT that when the edge of the implant impinged areas with an irregular surface profile, adherence occurred with more trouble, and the device had to be slightly shifted to cover an area of a smoother surface. This may be less likely to occur when EK is performed.

EndoArt is made of an acrylic hydrophobic material that creates an impermeable barrier to aqueous humor penetration into the central cornea over an area of 33.1  $\text{mm}^2$ , accounting for approximately 30% of the entire cornea. Stromal deturgescence is achieved by fluid evapora-

tion on the surface of the cornea. Therefore, the deturgescence effect of this device is most effective in the central cornea (6 mm) and less in the periphery, where stromal edema with epithelial bullae usually persists. Despite this, we observed pain reduction in all patients, testified by NRS score reduction from preoperative to 6 months after the surgery, indicating a positive impact of device implantation on the patient’s quality of life. The pain relief obtained in our study may be more enduring compared with other treatments used for painful BK.<sup>18</sup> In this regard, EndoArt may be applicable for the treatment of patients with symptomatic BK, regardless of visual potential.

Device biocompatibility is the ability of a medical or technological device to perform its intended function within or on the human body, without causing harmful effects or adverse reactions. Therefore, a biocompatible device should not elicit significant immune responses, toxicity, or other negative effects that could harm the patient. None of the cases in this series showed the signs of inflammation in the AC, corneal vascularization, or stromal melting, suggesting alterations in ocular and corneal homeostasis after EndoArt implantation. Furthermore, none of our patients required device explantation during the time covered by this study period suggesting a good safety profile of this device in the short term. However, further studies including a larger number of patients and a longer follow-up time to better assess the safety profile of EndoArt.

We used IVCN to investigate *in vivo* the morphological changes and biological interactions between the device and the patient’s cornea. Our analysis evidenced low-grade inflammation of the corneal stroma witnessed by the scarcity of reactive elements such as dendritic cells and activated

keratocytes, suggesting a good level of biological acceptance of the device.<sup>19,20</sup> The acellular inert properties of the implant may explain the relative absence of an inflammatory component. The alterations observed at the subbasal nervous plexus are likely ascribable to the previous long-standing BK<sup>21,22</sup> rather than a consequence of the stromal rearrangement induced by EndoArt. Interestingly, in none of the patients, we observed cells in the virtual space between the implant and posterior stroma, suggesting an inflammatory process occurring at the level of contact between the device and cornea.

The best candidate for artificial endothelial replacement membrane implantation remains to be defined. Our preliminary experience with this device may suggest that patients at high risk of LEF after one or more failed EK procedures with or without other ocular comorbidities, including glaucoma or previous glaucoma surgery, may be suitable candidates for artificial endothelial replacement membrane implantation. In these patients, in the absence of comorbidities that may affect visual function, significant improvement in visual acuity may be expected. Furthermore, in our series, patients with comorbidities and limited visual improvement still benefited from device implantation for ocular discomfort symptoms. Clearly recognizing that EndoArt does not presently represent a competitive alternative to EK, should our result be confirmed by larger studies with longer follow-up, this device may provide a greater donor tissues availability in favor of patients with a better long term prognosis after EK. Patients with tube implants or incomplete iris-capsular diaphragms may be at higher risk of graft detachment due to the expected difficulty in maintaining an efficient air–gas tamponade effect; therefore, they may be considered more challenging candidates for this procedure because device adhesion to the posterior corneal surface is expected to occur with more difficulties than using EK. Further studies are required to establish the implantability of this device in patients with previously failed PK.

In conclusion, our study confirms the efficacy of EndoArt in promoting stromal deturgescence and restoring central corneal transparency in patients with LEF after EK, demonstrating the capability of this device to improve visual function in patients with visual potential.

## ACKNOWLEDGMENTS

*The work reported in this publication was funded by the Italian Ministry of Health, RC-n. project 2023-2780760. All the authors of this manuscript received no funding for this research.*

## REFERENCES

- Price MO, Feng MT, Price FW. Endothelial keratoplasty update 2020. *Cornea*. 2021;40:541–547.
- Eye Bank Association of America 2022 Eye Banking Statistical Report. Available at: <https://restoresight.org/members/publications/statistical-report/>. Accessed July 21, 2023.
- Ham L, Dapena I, Liarakos VS, et al. Midterm results of Descemet membrane endothelial keratoplasty: 4 to 7 years clinical outcome. *Am J Ophthalmol*. 2016;171:113–121.
- Birbal RS, Ni Dhubhghaill S, Bourgonje VJA, et al. Five-year graft survival and clinical outcomes of 500 consecutive cases after Descemet membrane endothelial keratoplasty. *Cornea*. 2020;39:290–297.
- Price MO, Fairchild KM, Price DA, et al. Descemet's stripping endothelial keratoplasty five-year graft survival and endothelial cell loss. *Ophthalmology*. 2011;118:725–729.
- Ang M, Soh Y, Htoon HM, et al. Five-year graft survival comparing Descemet stripping automated endothelial keratoplasty and penetrating keratoplasty. *Ophthalmology*. 2016;123:1646–1652.
- Zafar S, Wang P, Woreta FA, et al. Risk factors for repeat keratoplasty after endothelial keratoplasty in the medicare population. *Am J Ophthalmol*. 2021;221:287–298.
- Dickman MM, Spekrijse LS, Dunker SL, et al. Long-term outcomes of repeated corneal transplantations: a prospective Dutch registry study. *Am J Ophthalmol*. 2018;193:156–165.
- Aboshiha J, Jones MNA, Hopkinson CL, et al. Differential survival of penetrating and lamellar transplants in management of failed corneal grafts. *JAMA Ophthalmol*. 2018;136:859–865.
- Cohen E, Mimouni M, Sorkin N, et al. Risk factors for repeat Descemet membrane endothelial keratoplasty graft failure. *Am J Ophthalmol*. 2021;226:165–171.
- Thong ISK, Jensen MP, Miró J, et al. The validity of pain intensity measures: what do the NRS, VAS, VRS, and FPS-R measure? *Scand J Pain*. 2018;18:99–107.
- Mencucci R, Cennamo M, Favuzza E, et al. Triphasic polymeric corneal coating gel versus a balanced salt solution irrigation during cataract surgery: a postoperative anterior segment optical coherence tomography analysis and confocal microscopy evaluation. *J Cataract Refract Surg*. 2019;45:1148–1155.
- Price MO, Price FW. Descemet stripping endothelial keratoplasty: fifteen-year outcomes. *Cornea*. 2023;42:449–455.
- Patel SV, Hodge DO, Winkler NS, et al. Graft survival, graft rejection and glaucoma in a consecutive series of Descemet stripping endothelial keratoplasty. *Cornea*. 2023;42:549–556.
- Bell KD, Campbell RJ, Bourne WM. Pathology of late endothelial failure: late endothelial failure of penetrating keratoplasty: study with light and electron microscopy. *Cornea*. 2000;19:40–46.
- Auffarth GU, Son HS, Koch M, et al. Implantation of an artificial endothelial layer for treatment of chronic corneal edema. *Cornea*. 2021;40:1633–1638.
- Aldave AJ, Chen JL, Zaman AS, et al. Outcomes after DSEK in 101 eyes with previous trabeculectomy and tube shunt implantation. *Cornea*. 2014;33:223–229.
- Sharma N, Roy S, Maharana PK, et al. Outcomes of corneal collagen crosslinking in pseudophakic bullous keratopathy. *Cornea*. 2014;33:243–246.
- Stachs O, Guthoff RF, Aumann S. In vivo confocal scanning laser microscopy. In: Bille JF, ed. *High Resolution Imaging in Microscopy and Ophthalmology: New Frontiers in Biomedical Optics*. Cham (CH): Springer; 2019. Chapter 12.
- Cruzat A, Qazi Y, Hamrah P. In vivo confocal microscopy of corneal nerves in Health and disease. *Ocul Surf*. 2017;15:15–47.
- Kobayashi A, Yokogawa H, Sugiyama K. In vivo laser confocal microscopy after non-Descemet's stripping automated endothelial keratoplasty. *Ophthalmology*. 2009;116:1306–1313.
- Shimizu T, Hayashi T, Ishida A, et al. Evaluation of corneal nerves and dendritic cells by in vivo confocal microscopy after Descemet's membrane keratoplasty for bullous keratopathy. *Sci Rep*. 2022;12:6936.