

FROM THE COVER

Artificial DMEK could help tackle endothelial donor tissue shortage

Newly developed acrylic implant can safely restore corneal homeostasis

By Dr Victor A. Augustin, Dr Maximilian K. Köppe and Prof. Gerd U. Auffarth



Dr Augustin



Dr Köppe



Dr Auffarth

Over 115 years ago, in 1905, Eudard Zirm successfully performed the first corneal transplantation.¹ Penetrating keratoplasties remained the gold standard for the treatment of a variety of corneal conditions for much of the 20th century.

More recently, in 1998, Melles and colleagues successfully attached a posterior lamellar graft consisting of stroma, Descemet membrane and endothelium to the posterior surface of the cornea, which initiated a new era in the treatment of corneal diseases primarily affecting the endothelium.² In 2006, Melles and associates first described the selective transplantation of the endothelium and Descemet membrane (EDM).³

Descemet membrane endothelial keratoplasty (DMEK) involves the surgical removal of the diseased endothelial layer as well as the diseased Descemet's membrane from the posterior corneal stroma.⁴ In comparison with traditional full-thickness or penetrating keratoplasty, DMEK allows the patient faster visual recovery, better refractive outcome and superior tectonic integrity.⁵⁻⁷

At present, endothelial keratoplasties such as DMEK are the gold standard in endothelial dysfunction,⁸ including Fuchs' endothelial dystrophy;⁸ pseudophakic bullous keratopathy;⁹ graft failure after penetrating or endothelial keratoplasty;⁹ pseudoexfoliation syndrome keratopathy;⁹ and endothelial decompensation due to congenital glaucoma.¹⁰ Known complications such as primary or secondary graft failure, immunological graft rejection and interface keratitis remain a challenge and can have a negative impact on the success of the procedure.^{8,11,12}

Nowadays, donor tissue preparation and insertion

into the anterior chamber is routine. However, rupture of the EDM during preparation can lead to graft loss, which can delay surgical intervention and disrupt organisational processes in a clinic.¹² Furthermore, prolonged or careless manipulation of the EDM in the anterior chamber can lead to significant endothelial loss. This can potentially cause primary or "early" secondary graft failure.¹²

According to a report published by the German Keratopathy Registry, the majority of keratoplasties performed these days are posterior lamellar keratoplasties; only 30% are penetrating keratoplasties.¹³ Additionally, because human donor corneas are in constant short supply,¹⁰ there is a need for alternative, universally available treatment options.

In 2018, Kinoshita and associates proposed the injection of cultured human corneal endothelial cells supplemented with a rho-associated protein kinase inhibitor into the anterior chamber to increase corneal endothelial cell density.¹⁴ A 5-year follow up published in 2020 by Numa and colleagues confirmed the safety and efficacy of this approach, however, it was tested only in a very small number of patients and further long-term data do not yet exist.¹⁵

Another recently introduced technique with no

IN SHORT

► **An innovative artificial lamella may provide a treatment option for patients for whom endothelial keratoplasty is unsuitable as well as providing a synthetic alternative to donor endothelial tissue.**


need for donor corneal tissue is Descemet membrane stripping only (DSO) with or without the topical treatment of rho kinase inhibitors. DSO involves removing a small area of central endothelium that has become dysfunctional, without performing an endothelial keratoplasty.¹⁶

This method has proven successful in a small number of patients with Fuchs endothelial dystrophy, however, its long-term efficacy has yet to be evaluated.¹⁶ A very limited number of patients are eligible for this method because of the need for healthy peripheral endothelial cells as well as central corneal guttae.

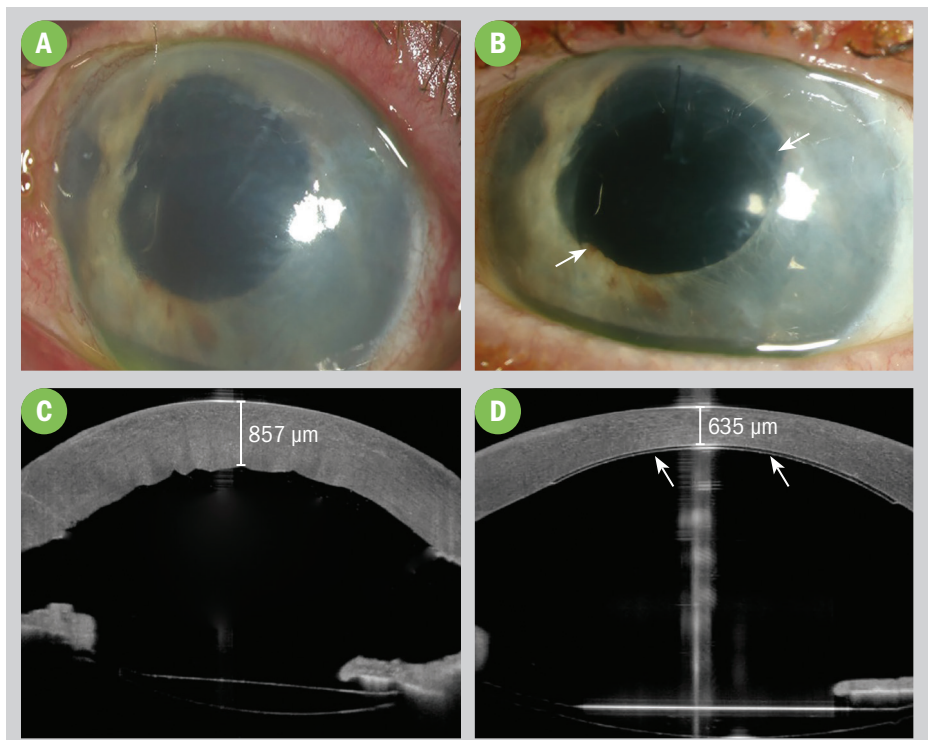
The artificial implant

A novel approach involves the implantation of an artificial endothelial layer to the posterior aspect of the cornea. The EndoArt (EyeYon Medical) is a flexible, hydrophilic, acrylic, dome-shaped permanent implant, 6 mm in diameter and 50 µm thick, specifically designed to replace the diseased corneal Descemet-endothelium layer (Figure 1). Implanting the lamella on the posterior surface of the cornea replaces the diseased endothelium and impedes the transfer of fluids into the central stroma. By covering around 40% of the back corneal surface, blocking the influx of fluids as well as epithelial evaporation leads to a reduction in corneal oedema to restore corneal homeostasis.

This artificial endothelial layer—which has been awarded CE certification, breakthrough therapy designation by the United States Food and Drug Administration (FDA) and China's Innovative Device Status—could provide a paradigm shift in the treatment of patients with endothelial failure while eliminating the need for human donor tissues.



(FIGURE 1) The implant.



(FIGURE 2) Slit-lamp pictures and OCT images before (A+C) and 12 weeks after implantation (B+D). Significant corneal oedema is shown in A and quantified via OCT in C. Marked resolution of corneal oedema 12 weeks after implantation is shown in B. Significant reduction in corneal thickness is measured by means of OCT in D. The white arrows show the outlines of the implant on the posterior surface of the cornea in B and D. (Images courtesy of IVCRC Heidelberg)

The Department of Ophthalmology of the University Eye Clinic in Heidelberg, Germany, was one of the first centres to implant this innovative device, with patients having completed 2 years' follow-up. The initial long-term evaluations are promising and demonstrate good safety and efficacy results. Currently, the implant is undergoing a first-in-human, multicentre trial across Europe and Asia.

The initial long-term evaluations are promising and demonstrate good safety and efficacy results.

Surgical technique

A 9-mm ring marks the central corneal surface to outline the peripheral extent of the Descemet membrane excision. With two paracentesis incisions at the 10 o'clock and 2 o'clock positions, the implant is folded into the cartridge of an IOL-injector and injected through a 2.2-mm clear cornea incision into the anterior chamber of the eye. The lamella then unfolds itself and is manually positioned onto the posterior corneal surface using an air bubble technique, similar to a DMEK procedure.

Unlike a human donor lamella, the implant can actually be touched and moved by the surgeon, using a cannula, without compromising its function. The experienced corneal surgeon who is already familiar with the DMEK procedure should be able to place the implant without the need for extra training. Cataract surgeons may require a few extra training sessions.

The Heidelberg experience: case report

A 79-year-old man presented to our clinic after complicated cataract surgery at a private practice. DMEK was not a treatment option because of his wide and non-light reactive pupil and anterior synechiae. The patient was complaining of decreased vision.

On examination, the patient showed significant corneal oedema with corneal bullae and reminiscent lens material in

the anterior chamber of the left eye. The patient perceived finger count with the left eye. An epiretinal gliosis was present on both eyes and the patient had received cryotherapy on the left eye due to a retinal tear 10 years earlier.

Figure 2 shows the diseased cornea before and after implantation. After 12 weeks, the cornea was clear with only a slight residual peripheral oedema (Figure 2 B+D). Corneal thickness was stable at 635 µm and visual acuity increased to 20/200 Snellen (Figure 2 D).

Retinal optical coherence tomography imaging revealed a pre-existing macular oedema, which is currently the limiting factor for visual improvement. The patient is being treated with parabolbar injections of steroids and further visual improvement is expected.

Conclusion

In conclusion, the technique described shows that an artificial endothelial layer is feasible for treatment of patients with endothelial dysfunction. This shows promise for overcoming the worldwide shortage of donor endothelial tissue. Furthermore, in cases where endothelial keratoplasty may not be possible, this may be a readily available treatment option.

REFERENCES

1. Zirm EK. Eine erfolgreiche totale Keratoplastik (A successful total keratoplasty). *Refract Corneal Surg.* 1989;5:258-261.
2. Melles GR, Eggink FA, Lander F, et al. A surgical technique for posterior lamellar keratoplasty. *Cornea.* 1998;17:618-626.
3. Melles GR, Ong TS, Ververs B, et al. Descemet membrane endothelial keratoplasty (DMEK). *Cornea.* 2006;25:987-990.
4. Kruse FE, Schrehardt US, Tourtas T. Optimizing outcomes with Descemet's membrane endothelial keratoplasty. *Curr Opin Ophthalmol.* 2014;25:325-334.
5. Dapena I, Ham L, Melles GR. Endothelial keratoplasty: DSEK/DSAEK or DMEK—the thinner the better? *Curr Opin Ophthalmol.* 2009;20:299-307.
6. Melles GR, Ong TS, Ververs B, et al. Preliminary clinical results of Descemet membrane endothelial keratoplasty. *Am J Ophthalmol.* 2008;145:222-227.
7. Price MO, Price FW, Jr. Endothelial keratoplasty – a review. *Clin Exp Ophthalmol.* 2010;38:128-140.
8. Seitz B, Daas L, Flockerzi E, et al. "Descemet membrane endothelial keratoplasty" DMEK – Spender und Empfänger Schritt für Schritt. *Der Ophthalmologe.* 2020;117:811-828.

9. Anshu A, Price MO, Tan DT, et al. Endothelial keratoplasty: a revolution in evolution. *Surv Ophthalmol.* 2012;57:236-252.
10. Asi F, Milioti G, Seitz B. Descemet membrane endothelial keratoplasty for corneal decompensation caused by herpes simplex virus endotheliitis. *J Cataract Refract Surg.* 2018;44:106-108.
11. Hos D, Matthaai M, Bock F, et al. Immune reactions after modern lamellar (DALK, DSAEK, DMEK) versus conventional penetrating corneal transplantation. *Prog Retin Eye Res.* 2019;73:100768.
12. Birbal RS, Baydoun L, Ham L, et al. Effect of surgical indication and preoperative lens status on Descemet membrane endothelial keratoplasty outcomes. *Am J Ophthalmol.* 2020;212:79-87.
13. Flockerzi E, Maier P, Böhlinger D, et al. Trends in corneal transplantation from 2001 to 2016 in Germany: A report of the DOG-section cornea and its keratoplasty registry. *Am J Ophthalmol.* 2018;188:91-98.
14. Kinoshita S, Koizumi N, Ueno M, et al. Injection of cultured cells with a ROCK inhibitor for bullous keratopathy. *N Engl J Med.* 2018;378:995-1003.
15. Numa K, Imai K, Ueno M, et al. Five-year follow-up of first 11 patients undergoing injection of cultured corneal endothelial cells for corneal endothelial failure. *Ophthalmology.* 2021;128:504-514.
16. Moloney G, Garcerant Congote D, Hirschschall N, et al. Descemet stripping only supplemented with topical ripasudil for Fuchs endothelial dystrophy 12-month outcomes of the Sydney Eye Hospital Study. *Cornea.* 2021;40:320-326.

VICTOR A. AUGUSTIN, MD, MAXIMILIAN K. KÖPPE, MD, AND GERD U. AUFFARTH, MD, FEBO

E: vic.augustin@googlemail.com

The authors are based at the David J. Apple International Laboratory for Ocular Pathology and International Vision Correction Research Centre (IVCRC), Department of Ophthalmology, University of Heidelberg, Germany. Drs Augustin and Köppe declare no conflicts of interest. Prof. Auffarth reports grants, personal fees, non-financial support and consulting fees from Johnson & Johnson and Alcon; grants, personal fees and non-financial support from Carl Zeiss Meditec, Hoya, Kowa, Oculentis/Teleon, Rayner, Santen, Sifi and Ursapharm; grants and personal fees from Biotech, Oculus and EyeYon; and grants from Acufocus, Anew, Contamac, Glaukos, Physiol and Rheacell, outside the submitted work.



Subscribe for practical tips and valuable resources